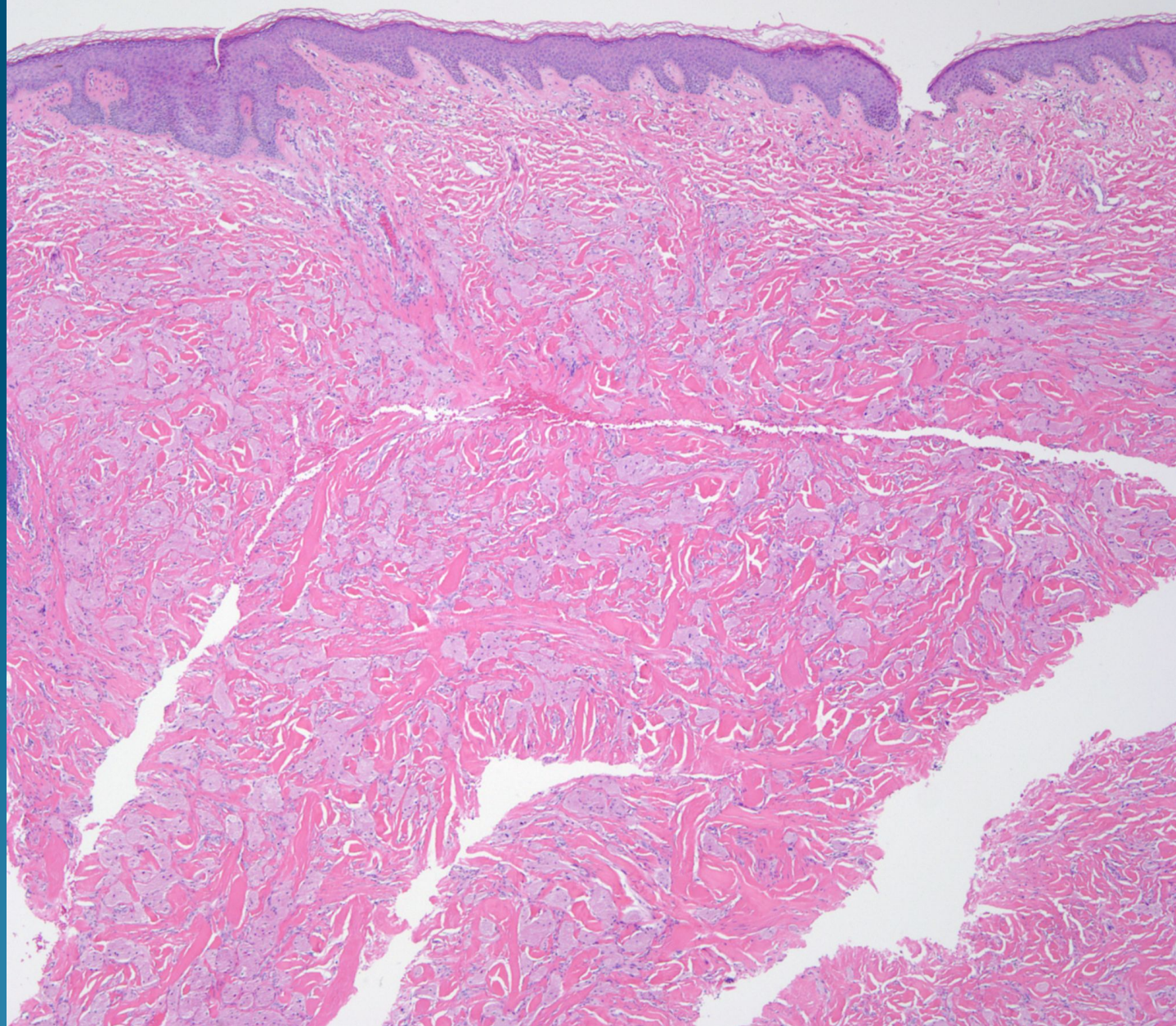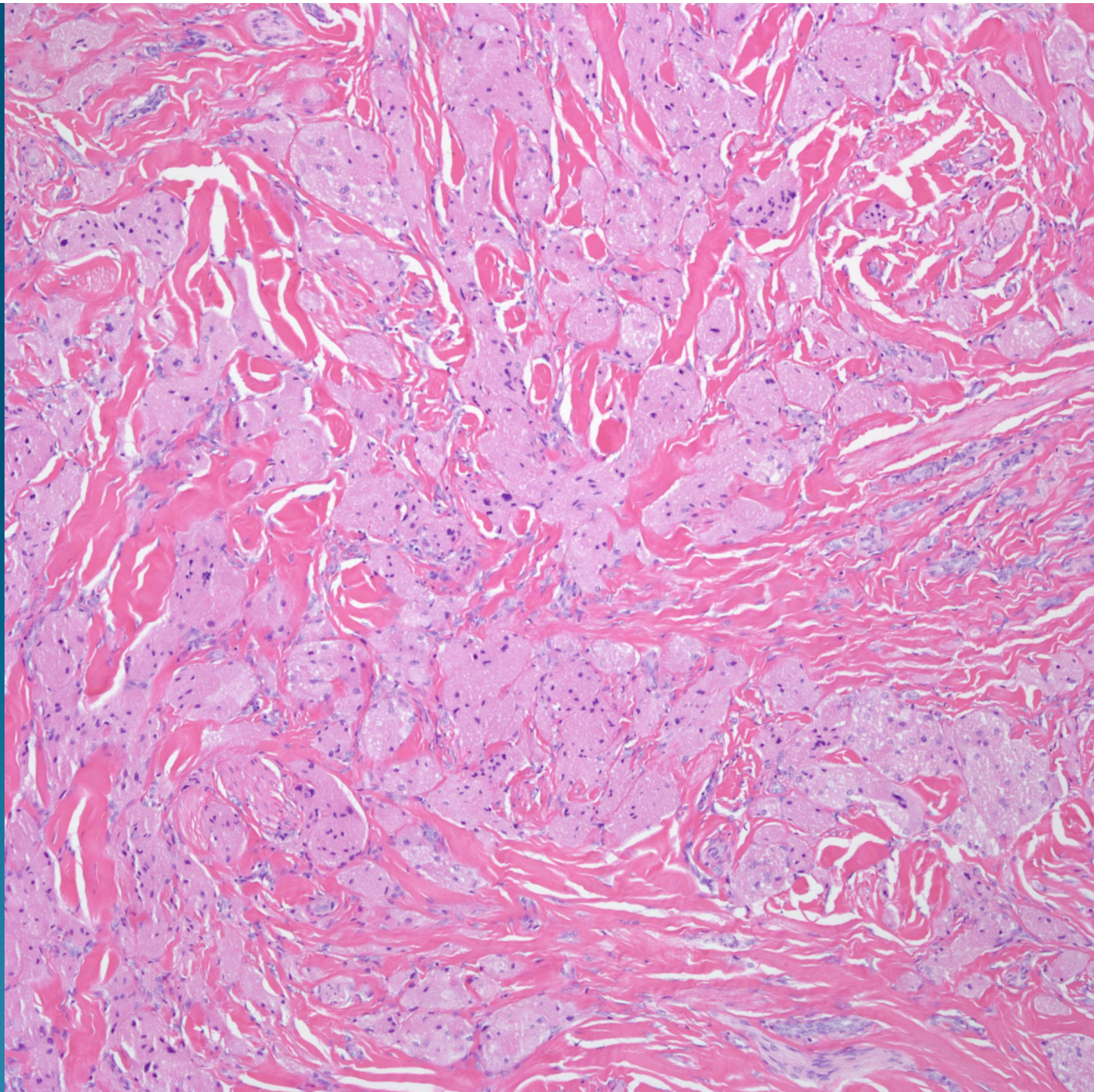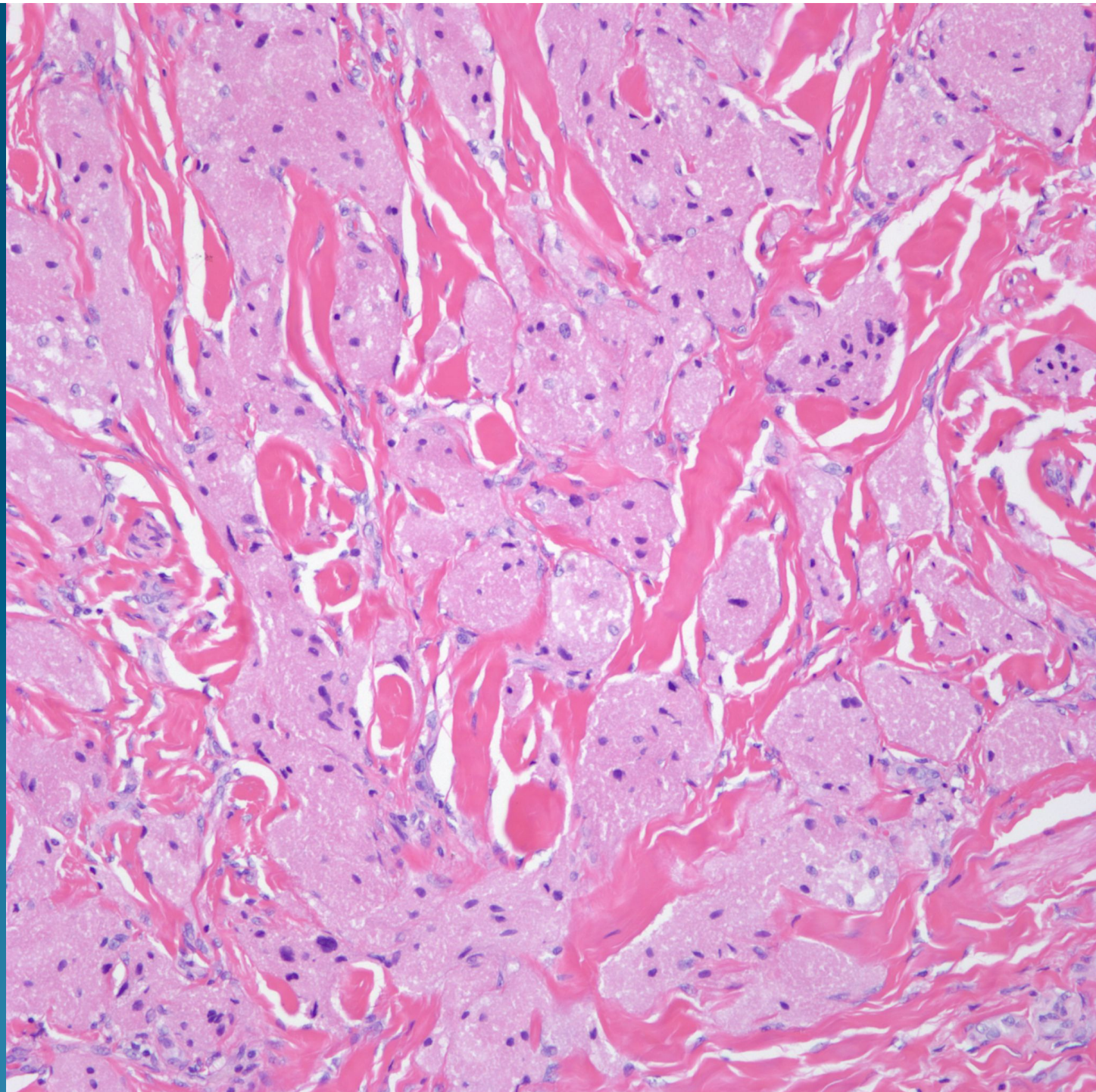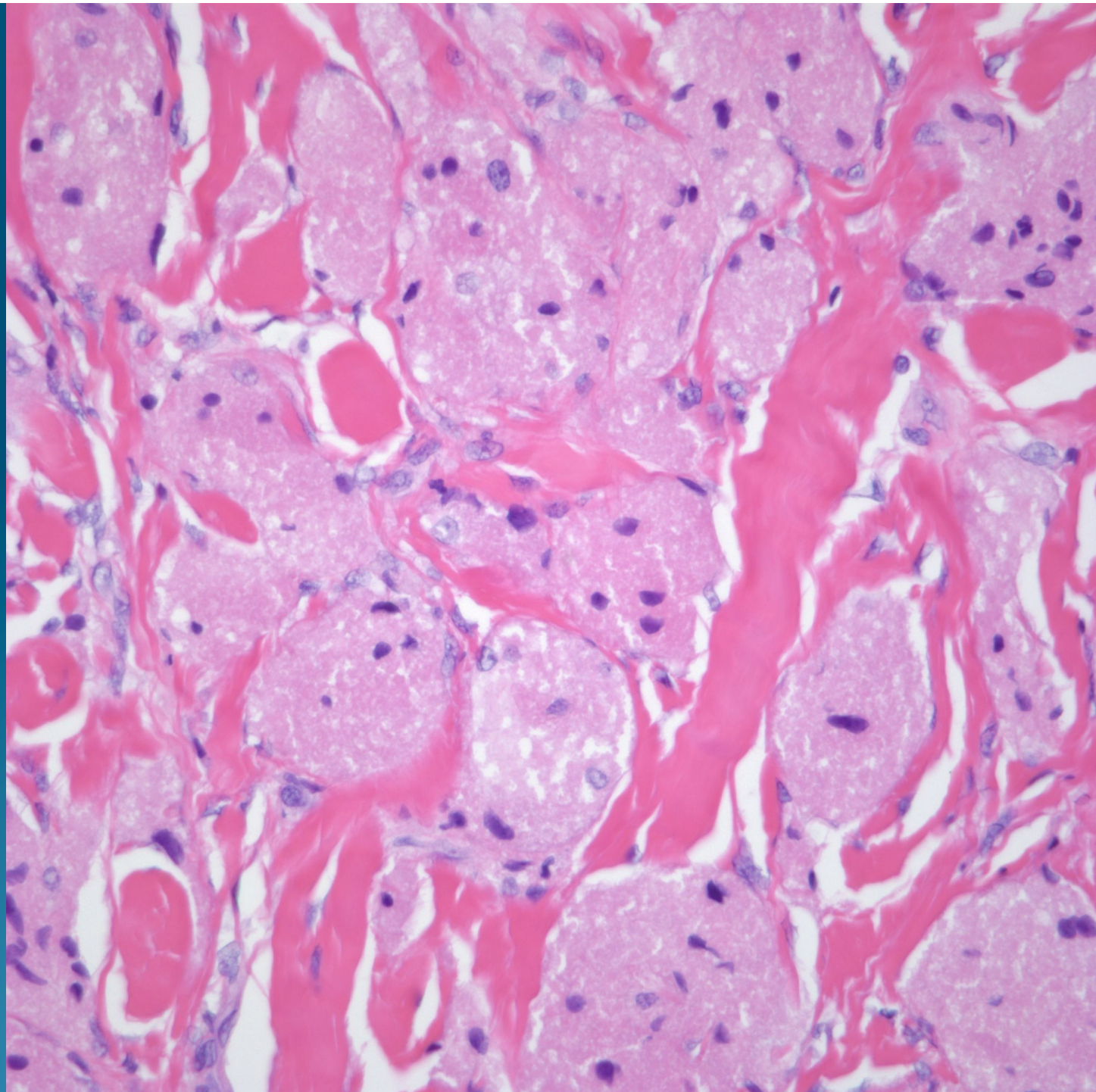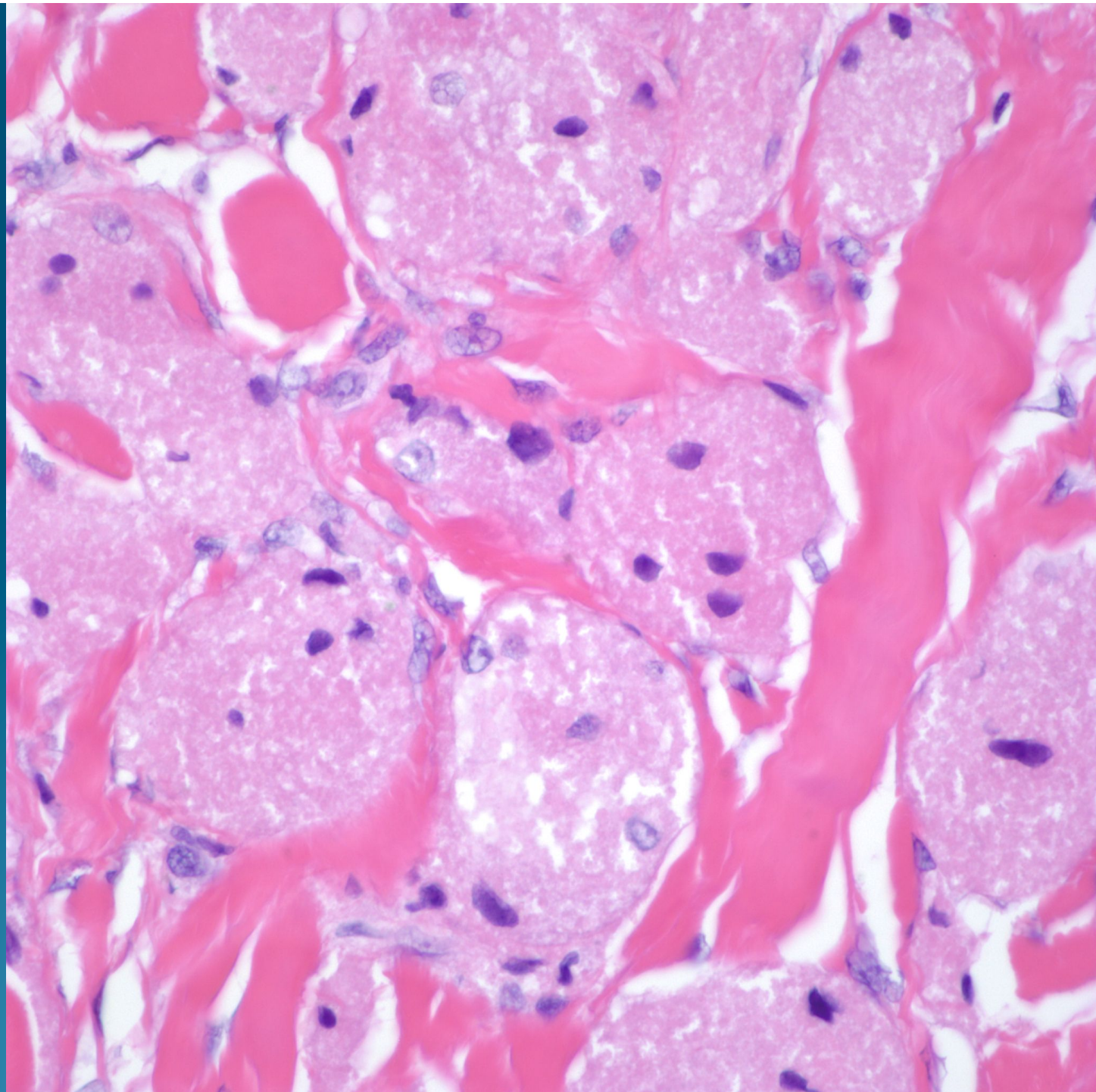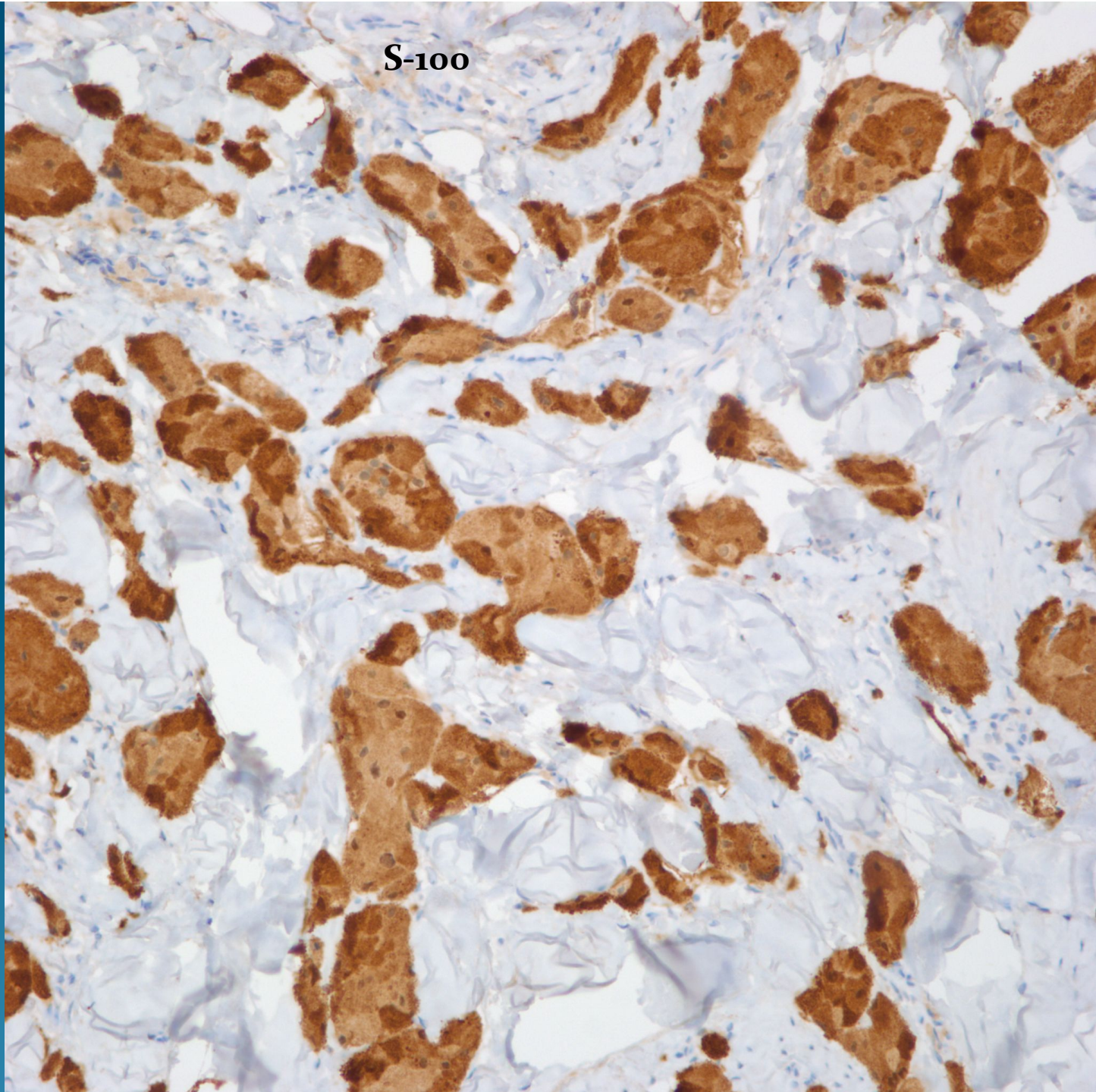


What is the best diagnosis?

- A. Dermal Spitz Nevus
- B. Rhabdomyosarcoma
- C. Rhabdomyoma
- D. Granular Cell Tumor
- E. Hibernoma

Granular Cell Tumor

S-100



Notes

- Additional stains including Cytokeratin, Smooth muscle actin, CD68 and MelanA were negative
- Granular cell changes may be seen in many neoplasms including carcinomas, smooth muscle neoplasms, and melanomas. Thus a complete immunohistochemistry panel is desirable to exclude these latter diagnostic possibilities.

Variable
Epidermal
Hyperplasia

Diffuse replacement of dermis
by nests and individual granular cells

Bland nuclear features
of Granular cells

